



Evidence of a modality-dependent role of the cerebellum in working memory? An fMRI study comparing verbal and abstract n-back tasks

Hubertus Hautzel^{a,b,*}, Felix M. Mottaghy^{a,c}, Karsten Specht^{d,e}, Hans-Wilhelm Müller^{a,b}, Bernd J. Krause^{a,f}

^a Department of Nuclear Medicine (KME), Forschungszentrum Jülich 52426, Jülich, Germany

^b Department of Nuclear Medicine, Heinrich-Heine-Universität, Düsseldorf, Germany

^c Department of Nuclear Medicine, University Hospital, Katholieke Universiteit Leuven, Leuven, Belgium

^d Department of Biological and Medical Psychology, University of Bergen, Bergen, Norway

^e Clinical Engineering Department, Haukeland University Hospital, Bergen, Norway

^f Klinik und Poliklinik für Nuklearmedizin, Klinikum rechts der Isar, Technische Universität München, Munich, Germany

ARTICLE INFO

Article history:

Received 22 September 2008

Revised 13 May 2009

Accepted 1 June 2009

Available online 11 June 2009

Keywords:

Central executive

Verbal working memory

Abstract working memory

Cerebellum

fMRI

ABSTRACT

In working memory (WM), functional imaging studies demonstrate cerebellar involvement indicating a cognitive role of the cerebellum. These cognitive contributions were predominantly interpreted as part of the phonological loop within the Baddeley model of WM. However, those underlying investigations were performed in the context of visual verbal WM which could pose a bias when interpreting the results. The aim of this fMRI study was to address the question of whether the cerebellum supports additional aspects of WM in the context of higher cognitive functions. Furthermore, laterality effects were investigated to further disentangle the cerebellar role in the context of the phonological loop and the visuospatial sketchpad. A direct comparison of verbal and abstract visual WM was performed in 17 young volunteers by applying a 2-back paradigm and extracting the % change in BOLD signal from the fMRI data. To minimize potential verbal strategies, Attneave and Arnoult shapes of non-nameable objects were chosen for the abstract condition. The analyses revealed no significant differences in verbal vs. abstract WM. Moreover, no laterality effects were demonstrated in both verbal and abstract WM. These results provide further evidence of a broader cognitive involvement of the cerebellum in WM that is not only confined to the phonological loop but also supports central executive subfunctions. The fact that no lateralization effects are found might be attributed to the characteristics of the n-back paradigm which emphasizes central executive subfunctions over the subsidiary slave systems.

© 2009 Elsevier Inc. All rights reserved.

Introduction

It has been repeatedly demonstrated that the cerebellum is essentially involved in the control and integration of motor activity. However, over the last two decades, evidence has also been generated with regard to a cerebellar role in cognition (Desmond and Fiez, 1998; Fiez, 2001b; Marien et al., 2001; Schmahmann, 1991, 2004; Schmahmann and Sherman, 1998). Studies on patients with cerebellar lesions and neuroimaging studies on healthy volunteers revealed a cerebellar contribution to executive functions such as planning, temporal sequencing, attention, learning and memory as well as an involvement in language processes (for review see e.g. Ackermann et al., 2007; Bellebaum and Daum, 2007; Ben-Yehudah et al., 2007; Haarmeier and Thier, 2007; Hokkanen et al., 2006; Leggio et al., 2008; Marien et al., 2001; Timmann and Daum, 2007). Accordingly, a number of studies focusing on working memory (WM) reported neuronal activity in the

cerebellum in addition to the well-known fronto-parietal neocortical network (Cabeza and Nyberg, 2000; Desmond et al., 1997; Fiez, 2001a; Gruber, 2001; Gruber and von Cramon, 2003; Hautzel et al., 2002, 2003; Krause et al., 2006; Owen et al., 2005; Paulesu et al., 1993). This neuronal network activated by WM tasks is discussed predominantly in the highly influential work of Baddeley (1986), Baddeley and Hitch (1974), and Repovs and Baddeley (2006). From this theoretical perspective, the cerebellum and Broca's area were interpreted to form a subvocal rehearsal process (Chen and Desmond, 2005a, 2005b; Desmond et al., 1997; Paulesu et al., 1993). In combination with the phonological store, this subvocal rehearsal builds the phonological loop – one of the content-specific components used to maintain different types of information (Baddeley, 2000). The main function of the subvocal rehearsal process is to actively refresh the information items in the phonological store. However, only a few studies tackled the issue of the cerebellar function in WM directly (Chen and Desmond, 2005b; Chen and Desmond, 2005a; Desmond et al., 1997; Desmond et al., 2005; Hokkanen et al., 2006; Mathiak et al., 2004). Desmond and Fiez postulate a more prominent role of the cerebellum in WM when

* Corresponding author. Department of Nuclear Medicine (KME), Forschungszentrum Jülich 52426, Jülich, Germany. Fax: +49 2461 611691.

E-mail address: h.hautzel@fz-juelich.de (H. Hautzel).

general task demands and/or memory load increase, respectively (Desmond and Fiez, 1998). However, studies specifically focusing on WM and the cerebellum have tested cerebellar function primarily within verbal WM (Chen and Desmond, 2005a, 2005b; Chiricozzi et al., 2008; Desmond et al., 1997, 2005; Fiez, 2001a; Paulesu et al., 1993). Consequently, the results have been discussed in the context of the phonological loop and its subsystems, leading to the conclusion that parts of the cerebellum subserve the rehearsal system, while others belong to the phonological store (Chiricozzi et al., 2008; Desmond et al., 1997). In addition, by applying exclusively visual verbal WM, the Desmond group revealed a right-sided laterality effect with the involvement of lobules VI and crus1 in subvocal rehearsal processes, while right lobules VIIb and VIII were found to contribute to the phonological store (Chen and Desmond, 2005a, 2005b; Desmond et al., 1997, 2003, 2005; Kirschen et al., 2005). However, the work of Kirschen et al. also presented evidence of an activation of the contralateral lobules as well, despite the fact that these left-sided contributions were less extended and less significant. Studies in lesioned patients failed to replicate a clear-cut right-sided lateralization of WM functions in the cerebellum. Concerning the visuospatial sketchpad, a study has yet to address the question of a cerebellar contribution to this WM subsystem directly but data derived from patients with unilateral left-sided cerebellar damage point towards a higher impairment in a visuospatial task compared to a right-sided lesion within the cerebellum (Hokkanen et al., 2006). Overall, the issue of cerebellar laterality in WM requires further evaluation.

In addition to verbal WM, other modalities employing object, spatial or abstract shape stimuli also induce cerebellar activations (Courtney et al., 1996; Hautzel et al., 2002; Nystrom et al., 2000; Pessoa and Ungerleider, 2004). This could be indicative of a more general role of the cerebellum within WM beyond its function in subordinate routines closely related to motor processes like inner speech. Evidence of extended cerebellar contributions to WM can be found in studies by Mathiak et al. testing WM of time (Mathiak et al., 2004) and by Gottwald et al. investigating attention and other central executive functions in patients with cerebellar lesions (Gottwald et al., 2003, 2004). Moreover, Appollonio et al. interpreted WM impairments after cerebellar damage as secondary to an impairment of executive functions because after controlling for executive measures, memory scores were no longer different to those of healthy controls (Appollonio et al., 1993). Finally, the cerebellar cognitive affective syndrome (CCAS) summarizes an association of lesions to the posterior cerebellar lobe with deficits of executive functions (planning, set shifting, verbal fluency, abstract reasoning, and working memory) (Schmahmann and Caplan, 2006; Schmahmann and Sherman, 1998).

Given such divergent evidence concerning the role of the cerebellum, the aim of the fMRI study presented here was twofold: (1) to directly address the question of whether the cerebellum processes the predominantly language-related aspects of WM or whether it is also involved in higher-order cognitive WM processes, and (2) to evaluate laterality effects of the cerebellum at the hemisphere and the lobular levels for both the verbal and abstract WM separately.

In order to maximize the differences of speech input, we performed a direct intra-individual comparison of verbal WM and abstract shape WM using non-nameable polygons as stimuli for the latter constructed according to method 1 described by Attneave and Arnoult (1956). Furthermore, to ensure adequate comparability between modalities and underlying processes and particularly to stress the central executive subfunctions of time coding and updating, an n-back WM task was chosen instead of a delayed match-to-sample paradigm (Peters et al., 2005; Smith and Jonides, 1997; Wager and Smith, 2003). If the cerebellum is predominantly involved in subvocal rehearsal processes, we hypothesized an intense activation of neocerebellar structures during the verbal WM task but not while performing the abstract WM

paradigm. In addition, predominantly right-sided cerebellar activations should be evident as a result of the crossed cerebello-cortical diaschisis (Botez-Marquard et al., 1994; Broich et al., 1987; Pantano et al., 1986). If the abstract WM recruits cerebellar regions in the context of the visuospatial sketchpad in analogy to verbal WM and the phonological loop, then a left-sided lateralization in the abstract WM activation patterns should result. On the other hand, if higher cognitive functions summarized in the central executive are the major cause of cerebellar activation, both tasks should reveal comparable signal increases in the cerebellum. From the neocortical perspective, both WM paradigms have been proven to activate the central executive core areas in prefrontal and parietal cortices bilaterally and to the same extent (Hautzel et al., 2002). If this alternative hypothesis of cerebellar involvement beyond the subordinate WM slave systems and particularly beyond the phonological loop holds true, then the resulting neuronal activations should be symmetrically distributed over both cerebellar hemispheres.

Methods and materials

Subjects

Seventeen right-handed healthy male subjects (mean age 25.7 +/− 3.8 years) participated in this fMRI study after giving written informed consent. The study was approved by the local ethics committee. Part of the data was published in an earlier paper (Hautzel et al., 2002). In this re-evaluation of the data, the focus was laid specifically on the analysis of the contribution of the cerebellum to the different working memory tasks.

Working memory tasks

For stimulus presentation and response data collection via button press, the ERTS software (Berisoft Cooperation, Frankfurt, Germany) was used. All stimuli were presented for 1.3 s with an interstimulus interval of 200 ms. In both WM modalities two tasks were performed: 2-back and 0-back as a reference task. In the 2-back task, subjects had to decide whether the present stimulus matched the stimulus encountered two stimuli before, while in the 0-back task, predetermined stimuli indicated left or right button press responses. Letters served as stimuli in the verbal WM version, and Attneave and Arnoult structures were used as abstract non-nameable shape stimuli (Fig. 1) (Attneave and Arnoult, 1956). Stimuli were presented in a blocked design with three 2-back and three 0-back blocks separated by baseline blocks (fixation cross) with a block lengths of 30 s each. The two WM modalities were presented in separate runs in counter-balanced order.

Functional MRI

Whole-brain fMRI was performed on a 1.5 Tesla MRI scanner (Siemens Magnetom Vision, Erlangen, Germany) with the following technical details: gradient echo planar imaging (EPI) with repetition time = 5000 ms; echo time = 66 ms; 32 slices; field of view = 200 mm; flip angle (θ) = 90°; matrix size = 64 × 64 giving




Fig. 1. Abstract non-nameable stimuli generated according to method 1 of Attneave and Arnoult.

an in-plane pixel size of $3.13 \times 3.13 \text{ mm}^2$ covering the whole brain. In addition, high-resolution anatomical images of the brain were obtained.

Data processing and analysis

Image preprocessing was performed using tools within SPM2 (The Wellcome Department of Imaging Neuroscience, www.fil.ion.ucl.ac.uk/spm/). After realignment and co-registration with the anatomical scans, the EPI images were transformed into a standard stereotactic space (MNI template) by setting the voxel size to $2 \times 2 \times 2 \text{ mm}^3$. To further account for the small anatomical structures of the cerebellum a 5 mm Gaussian filter was chosen for final image smoothing. Applying the general linear model within SPM2, intra-individual contrasts 2-back minus 0-back were calculated separately for verbal and abstract WM. Using these initial single-subject contrasts, group activation maps were computed in a second-order random effects analysis (one-sample *t*-test). Voxels with $p < 0.05$ corrected for multiple comparisons (false discovery rate; FDR) and belonging to a cluster of at least 20 activated voxels were identified as significantly activated.

To define the cerebellar volumes of interest (VOI) for the subsequent % signal change estimation a stepwise approach was chosen. At first a common WM analysis combining both verbal WM [2-back minus 0-back] and abstract WM [2-back minus 0-back] contrasts was computed to generate a modality independent functional contrast. Next anatomical VOIs of all cerebellar lobuli and the subsections of the vermis were defined using the WFU PickAtlas toolbox (version 2.0) within SPM2 (Maldjian et al., 2003, 2004). Thereafter, the significant voxel clusters from the initial common WM analysis, thresholded at $p < 0.05$ (FDR corrected) and a cluster size of 20 voxels, were collected in each of these anatomically defined VOIs to finally extract functionally defined VOIs. To account for the high anatomical variability of the dentate nuclei even after normalization to the MNI template (Dimitrova et al., 2006) individual VOIs of the dentate nuclei for each subject were created with the VOI tool of PMOD (version 3.0, PMOD technologies Ltd., Zurich, Switzerland). To this end, the normalized but unsmoothed mean EPI images were used on which the dentate nuclei are easily distinguishable due to their hypointense signal in comparison to the surrounding tissues. Using the functionally defined lobular/vermal VOIs and the individualized dentate nuclei VOIs, the average signals for the 2-back and the 0-back conditions were calculated in these VOIs for each subject according to the method implemented in the MarsBaR toolbox of SPM2 (MarsBaR, v0.38). After testing for normality (Kolmogorov–Smirnov test), one-sample *t*-tests were applied to identify significant differences in % signal change between 2-back and 0-back for the verbal and abstract WM modalities separately ($p < 0.05$ was regarded as significant). In addition, the coordinates of the suprathreshold SPM center of mass (CoM) activations of both the verbal and the abstract WM group analyses were collected for each functional VOI.

Finally, to address question (1) of a lobule-wise difference in cerebellar activation induced by verbal vs. abstract stimuli, the [2-back minus 0-back] differences in % signal change for verbal WM and abstract WM were directly compared in each individual VOI using a two-sided one-sample *t*-test with an initial significance level of $p < 0.05$ after applying a Bonferroni correction for the number of VOIs considered ($n = 25$). In order to identify very subtle differences in BOLD signal, the significance level was subsequently set to $p < 0.05$ uncorrected, taking into account that results from this analysis may not be generalized to the age-matched population. Concerning the second question of laterality effects firstly differences across the cerebellar hemispheres were tested applying separate analyses for verbal WM and abstract WM. To that end, all left hemispherical lobular results of the [2-back minus 0-back] % signal change estimations were compared to those of the right side by applying a

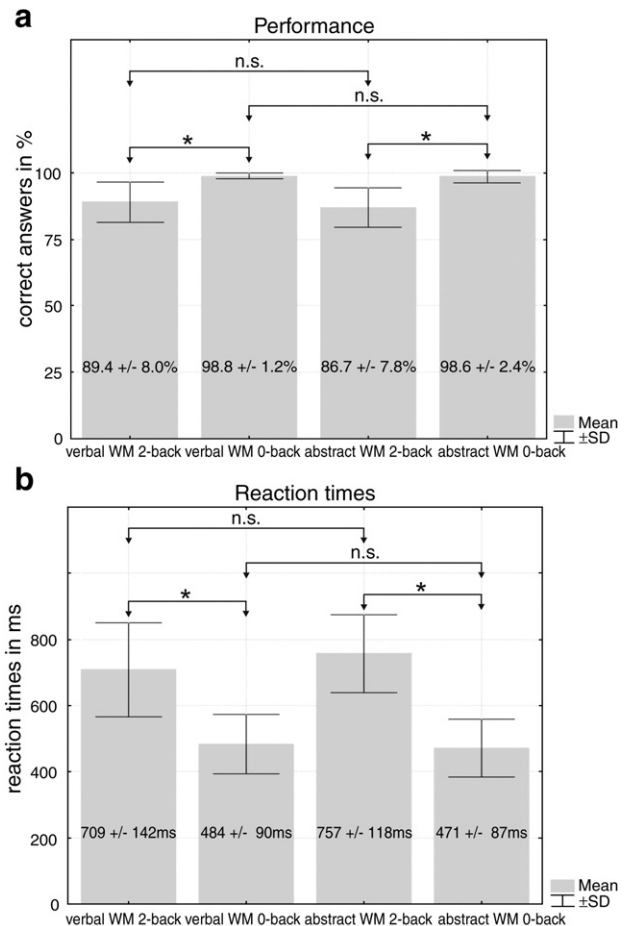


Fig. 2. Behavioral data: a) Correct answers in %. Left two bars: Verbal WM: 2-back and 0-back; Right two bars: Abstract WM: 2-back and 0-back. b) Reaction times in ms: Left two bars: Verbal WM: 2-back and 0-back; Right two bars: Abstract WM: 2-back and 0-back. * $p < 0.001$, n.s. not significant.

two-sided one-sample *t*-test ($p < 0.05$ was regarded as significant). In order to test for WM modality-specific laterality effects on the lobular level, two-sided one-sample *t*-tests were performed using the [2-back minus 0-back] % signal change of the corresponding left and right hemispherical cerebellar lobules and the dentate nuclei ($p < 0.05$ was regarded as significant after applying a Bonferroni correction for the 7 bilateral hemispheric VOIs considered in this comparison).

To test for any possible cerebral differences which might co-exist with potential differences in cerebellar activation patterns between verbal and abstract WM a cognitive subtraction of (verbal WM: [2-back minus 0-back]) vs. (abstract WM: [2-back minus 0-back]) and vice versa was added using SPM2. The statistical threshold was kept to the same levels ($p < 0.05$, FDR corrected, cluster size 20 voxels) as in all other SPM analyses described above.

The nomenclature of the lobular structures used was based on the three-dimensional atlas of the human cerebellum by [Schmahmann et al., 1999, 2000](#).

The collected behavioral data (performance and reaction time) were analyzed using paired *t*-tests ($p < 0.05$ was regarded as significant).

Results

Behavioral data

The results of the behavioral data are given in [Fig. 2](#). Accuracy and reaction times did not significantly differ between verbal WM and

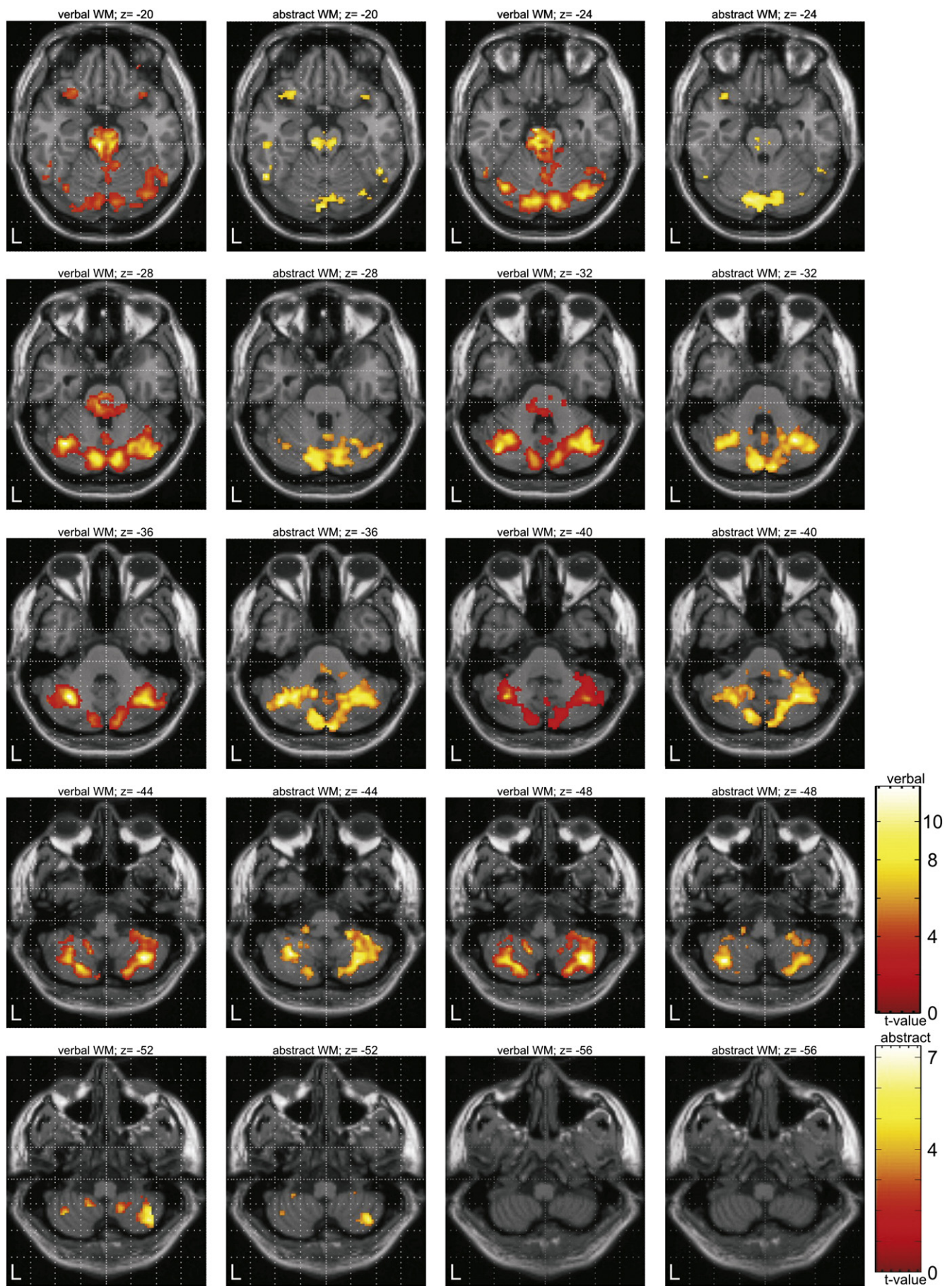


Table 1

Impact of a verbal and an abstract 2-back WM task on the BOLD signal in cerebellum: Centers of mass activation and *t*-values from the SPM analyses and % BOLD signal changes [2-back minus 0-back] for all cerebellar subregions (functionally defined VOIs), separated for verbal WM on the left and abstract WM on the right. *x y z* coordinates are in MNI space; % signal changes are given as mean \pm standard deviation of *n* = 17 subjects.

Cerebellar lobule	Verbal working memory					Abstract working memory				
	center of mass activation					center of mass activation				
	<i>x</i>	<i>y</i>	<i>z</i>	<i>t</i> value	% signal change	<i>x</i>	<i>y</i>	<i>z</i>	<i>t</i> value	% signal change
III left	No suprathreshold SPM cluster					No suprathreshold SPM cluster				
III right	No suprathreshold SPM cluster					No suprathreshold SPM cluster				
IV/V left	−4	−46	−16	3.48	0.16 \pm 0.20	−10	−46	−16	3.68	0.15 \pm 0.22
IV/V right	No suprathreshold SPM cluster					No suprathreshold SPM cluster				
VI left	−24	−64	−30	7.44	0.24 \pm 0.21	−26	−60	−32	7.08	0.23 \pm 0.37
VI right	30	−58	−36	9.44	0.32 \pm 0.25	28	−58	−36	6.54	0.26 \pm 0.43
Crus1 left	−38	−62	−38	9.57	0.40 \pm 0.19	−28	−62	−34	6.50	0.34 \pm 0.51
Crus1 right	34	−58	−38	17.39	0.39 \pm 0.20	40	−64	−36	6.90	0.35 \pm 0.48
Crus2 left	−38	−60	−40	8.61	0.32 \pm 0.19	−8	−86	−34	7.34	0.30 \pm 0.36
Crus2 right	6	−80	−28	8.19	0.34 \pm 0.21	4	−84	−32	6.41	0.33 \pm 0.33
VIIb left	−36	−64	−48	9.64	0.33 \pm 0.21	−32	−58	−42	6.14	0.26 \pm 0.28
VIIb right	38	−62	−48	5.99	0.34 \pm 0.23	38	−62	−48	6.85	0.28 \pm 0.33
VIII left	−34	−60	−48	9.50	0.26 \pm 0.20	−28	−58	−42	7.26	0.18 \pm 0.24
VIII right	32	−64	−50	7.99	0.26 \pm 0.19	32	−56	−44	7.38	0.20 \pm 0.28
IX left	−14	−54	−52	4.70	0.19 \pm 0.18	No suprathreshold SPM cluster				
IX right	14	−54	−48	6.08	0.16 \pm 0.13	12	−54	−36	5.13	0.11 \pm 0.27 n.s.
X left	No suprathreshold SPM cluster					−20	−38	−42	5.42	0.17 \pm 0.28
X right	No suprathreshold SPM cluster					No suprathreshold SPM cluster				
Vermis 1/2	4	−38	−22	4.56	0.19 \pm 0.35	No suprathreshold SPM cluster				
Vermis 3	−2	−46	−16	4.19	0.39 \pm 0.35	0	−38	−14	3.25	0.16 \pm 0.43 n.s.
Vermis 4/5	0	−48	−16	4.18	0.19 \pm 0.28	−2	−62	−16	3.77	0.21 \pm 0.66 n.s.
Vermis 6	0	−56	−24	4.04	0.20 \pm 0.23	0	−64	−16	3.61	0.24 \pm 0.37
Vermis 7	6	−78	−26	8.19	0.18 \pm 0.28	6	−76	−26	4.75	0.17 \pm 0.29
Vermis 8	0	−62	−28	4.20	0.29 \pm 0.26	0	−76	−26	4.75	0.32 \pm 0.44
Vermis 9	No suprathreshold SPM cluster					0	−58	−30	3.91	0.19 \pm 0.37
Vermis 10	No suprathreshold SPM cluster					0	−56	−30	4.36	0.19 \pm 0.33
Dentate nucl. left	No SPM group analysis, individual VOIs					No suprathreshold SPM cluster				
Dentate nucl. right	No SPM group analysis, individual VOIs					No SPM group analysis, individual VOIs				

No suprathreshold SPM cluster: The WM modality specific SPM analysis revealed no suprathreshold clusters in this VOI which was functionally defined by the common WM analysis; not included: In this anatomical region no functional VOIs was determined due to not significant results in the common WM analysis; n.s.: No significant BOLD signal difference between WM (2-back) and control (0-back) condition.

abstract WM (accuracy: $89.4 \pm 8.0\%$ vs. $86.7 \pm 7.8\%$, $p > 0.05$; reaction times: 709 ± 142 ms vs. 757 ± 118 ms, $p > 0.05$). However, accuracy was significantly higher in the reference conditions: verbal WM performance: 2-back $89.4 \pm 8.0\%$ vs. 0-back $98.8 \pm 1.2\%$ ($p < 0.001$); abstract WM performance: 2-back $86.7 \pm 7.8\%$ vs. 0-back $98.6 \pm 2.4\%$ ($p < 0.001$). Accordingly, reaction times were significantly longer while performing the WM tasks vs. controls: verbal WM: 2-back 709 ± 142 ms vs. 0-back 484 ± 90 ms ($p < 0.001$); abstract WM: 2-back 757 ± 118 ms vs. 0-back 471 ± 87 ms ($p < 0.001$).

Imaging data

Both the subtraction analyses of verbal WM [2-back minus 0-back] and that of the abstract WM [2-back minus 0-back] revealed similar activations in a fronto-parietal network including the anterior cingulate cortex. These cortical results have been described and discussed previously (Hautzel et al., 2002). The detailed functional VOI guided SPM analysis of the cerebellar contributions to verbal WM [2-back minus 0-back] demonstrated robust BOLD signal increases predominantly in the posterior lobes of both neocerebellar hemispheres. Significant activations were found in lobules VI, crus1, crus2, VIIb, VIII and IX and in the subsections 1/2, 3, 4/5, 6, 7 and 8 of the vermis (Fig. 3, first and third column, Table 1 for CoM coordinates and *t*-values). Enhanced fMRI signals induced by the abstract WM [2-back minus 0-back] were also located predominantly in the

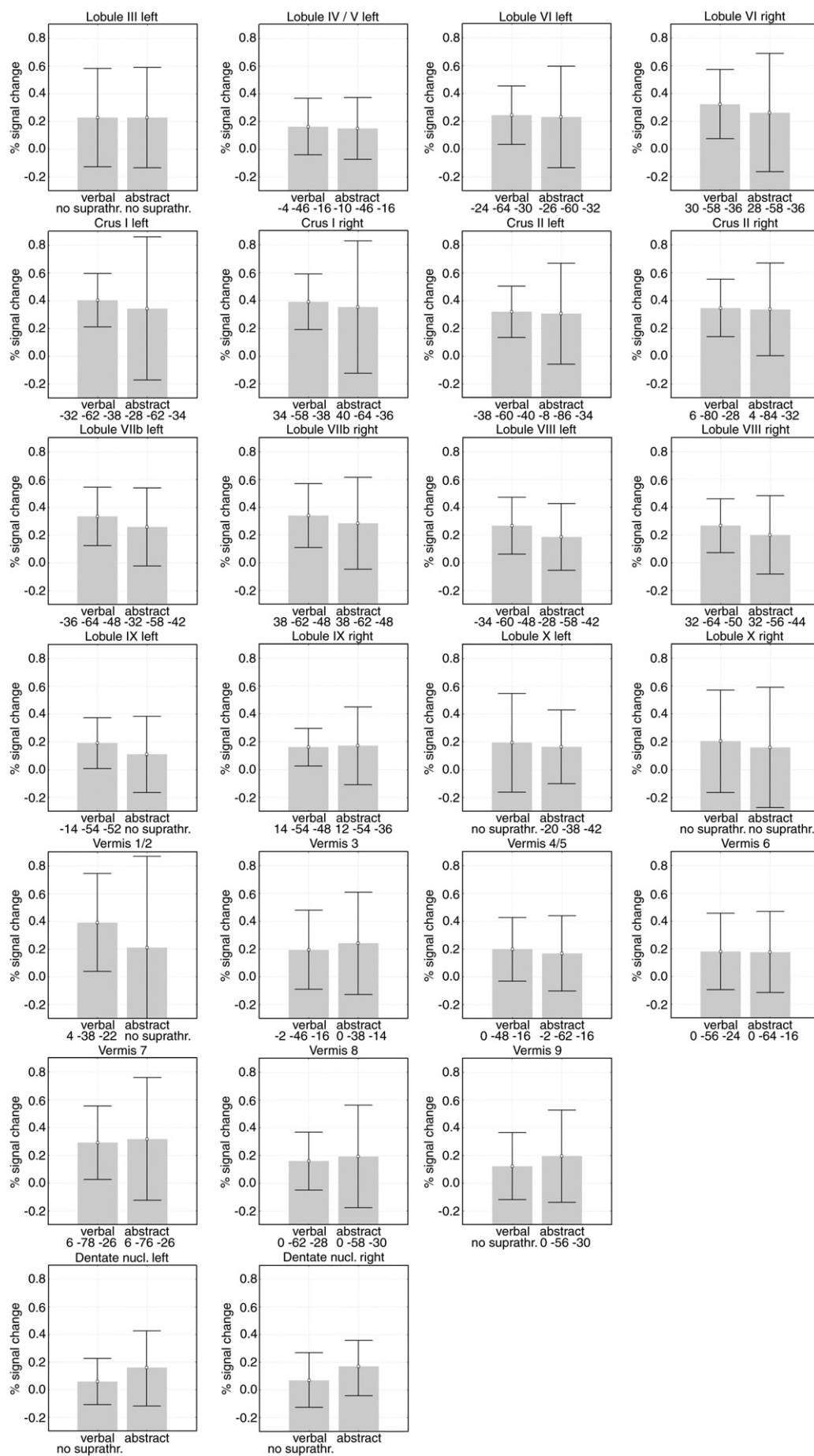
posterior lobe. Specifically, activations were found in lobules VI, crus1, crus2, VIIb, VIII and IX and in the vermal subsections 3, 4/5, 6, 7, 8 and 9 (Fig. 3, second and fourth column, Table 1 for CoM coordinates and *t*-values). In both WM modalities, small additional clusters were identified in left lobule IV/V.

After extracting the average signal from all functionally defined VOIs in every volunteer and for all conditions, the average % signal change in all lobular and vermal VOIs as well as for the dentate nuclei VOIs were calculated. Significant [2-back minus 0-back] differences were found for both verbal and abstract WM (Table 1). The % signal change analysis revealed a BOLD signal increase from 0.16 to 0.40 % in verbal WM and from 0.15 to 0.35 % in abstract WM, respectively. % BOLD signal changes, which did not survive the statistical threshold of $p < 0.05$ (indexed n.s. in Table 1), were observed in the functional VOIs of the dentate nucleus and vermis 9 (verbal WM) and left IX, right X and vermis 1/2 (abstract WM), respectively.

Aim 1

In order to identify possible modality specific differences in the cerebellar contribution to WM, the [2-back minus 0-back] % signal change differences in verbal WM were tested against those induced by abstract WM. However, no subregion demonstrated a significantly higher % signal change in the verbal as compared to the abstract condition or vice versa (Table 1 and Fig. 4). Even when applying the

Fig. 3. Pairwise illustrations of BOLD signal changes [2-back minus 0-back] for verbal WM (columns 1 and 3) and for abstract WM (columns 2 and 4) covering the cerebellum from $z = -20$ (upper left) to $z = -56$ (lower right). SPM activation maps (thresholded at $p < 0.05$, FDR corrected for multiple comparisons) are overlaid on an anatomical T1-weighted axial MRI scan. Conditions and *z*-coordinates are given on top of each slice. Corresponding center of mass coordinates, *t*-values and % signal change are given in Table 1.



lenient significance level of $p < 0.05$ uncorrected, no differences between the two WM modalities were apparent.

Aim 2

Searching for superordinate laterality effects on the hemispherical level, analyses revealed no differences in either verbal WM ($p = 0.54$) or abstract WM ($p = 0.25$).

Taking a more detailed look at laterality effects at the lobular levels, no signal lateralization was found as well in both the verbal and the abstract condition, even when an uncorrected significance measure of $p < 0.05$ was used.

The final cognitive subtraction of (verbal WM: [2-back minus 0-back]) vs. (abstract WM: [2-back minus 0-back]) and vice versa revealed neither at the cerebral level nor within the cerebellum any WM modality specific differences.

Discussion

The present study revealed an almost identical cerebellar activation pattern when comparing percent change of BOLD signal in a verbal WM task with an abstract WM task on a lobule by lobule basis and keeping the cognitive demands of the tasks at the same level. In addition, no laterality effects at the hemispherical or the lobular level were found in both WM modalities.

Since previous work on the cerebellum and WM interpreted results mainly as contributions of the subordinate slave systems, the two different modalities tested here should either involve the phonological loop (verbal stimuli) or the visuospatial sketchpad (abstract stimuli). Given the cerebro-cerebellar diachisis caused by the crossing neural connections between the cerebral cortex and the cerebellum, it is expected that cerebellar involvement in routines of the phonological loop will result in a right-sided lateralization of the activation maps. On the other hand, a visuospatial sketchpad-dependent activation should induce a left-dominant BOLD signal in the cerebellum. While our results could not reveal any cerebellar side asymmetries in verbal WM activations Desmond et al. reported right-sided laterality effects in the circumference of lobules VIIb/VIII (Chen and Desmond, 2005a, 2005b; Desmond et al., 1997, 2005; Kirschen et al., 2005). Those findings were additionally supported by a study on patients with cerebellar lesions, which revealed an impairment in a 2-back WM task using digits (Gottwald et al., 2003).

A predominantly right hemispheric cerebral activation has been reported for the visuospatial processing of WM stimuli (for review see e.g. Mottaghy, 2006; Suchan, 2008), which in turn is expected to interact together with the left cerebellum if this latter structure actually contributes to the visuospatial sketchpad. However, no lateralization effects were found in the abstract WM condition on either the hemispherical or the lobular level. Only one lesion study demonstrated a slowing down in a visuospatial task when the cerebellar lesion was located in the left hemisphere in addition to a general impairment in WM independent of the lesion side (Hokkanen et al., 2006).

The comparison of both WM modalities at the whole brain level revealed no differences in prefrontal or parietal regions which is indicative for an equivalent cerebral involvement in both tasks. As the cerebellar activation is at least in part driven by the superordinate cerebral activity it appears reasonable that the cerebellum is activated (a) to the same extent in verbal and abstract WM and (b) no laterality effects occur in either of the two WM modalities. One reason for this finding might be the use of the n-back paradigm instead of a Sternberg or delayed match-to-sample task. The n-back task emphasizes the manipulation of information and executive control more than stimulus

maintenance. Therefore the executive functions might dominate the contributions of the slave systems in this special n-back setting and possibly override underlying cerebellar asymmetries induced by the phonological loop and the visuospatial sketchpad.

The fact, that both the analyses of verbal WM and abstract WM demonstrated extended identical cerebellar activation patterns does not support a role of the cerebellum solely in the context of the articulatory control system of WM, as proposed by a number of studies (Awh et al., 1996; Desmond et al., 1997; Desmond and Fiez, 1998; Paulesu et al., 1993; Rypma et al., 1999; Salmon et al., 1996; Smith et al., 1998). The view of a pure auxiliary cerebellar function in subvocal rehearsal has been challenged additionally by behavioral studies in lesioned patients and controls: (A) articulatory suppression effects were not different from controls (Chiricozzi et al., 2008; Ravizza et al., 2006), and (B) the phonological similarity effect was not domain-dependent (visual vs. auditory) (Justus et al., 2005). Therefore, alternative and/or additional superordinate cerebellar contributions to WM have been proposed with a possible role in error-driven adjustment and/or internal timing (Ben-Yehudah et al., 2007).

As the above mentioned neuroimaging WM studies used visual verbal stimuli, an interpretation of the findings in the context of language seems obvious due to the well documented cerebellar involvement in speech processing and language (Fiez, 2001b; Marien et al., 2001; Petersen et al., 1988; Schirmer, 2004). However, our data point towards a more extended cerebellar functionality. The analysis of both verbal and abstract WM revealed widespread activations of the cerebellum in the posterior lobe. According to Baddeley's WM model, the subordinate slave systems are connected with the central executive (Baddeley, 1986, 2000). Beyond those subroutines, a contribution of the cerebellum to central executive functions therefore appears reasonable. A large body of evidence attributes the executive function to prefrontal and parietal cortices (D'Esposito et al., 2000; Petrides et al., 1993a, 1993b; Smith and Jonides, 1999). From a neuroanatomical perspective, the cerebellum is interconnected with these neocortical structures via crossing afferent corticopontocerebellar pathways projecting from the pons to the neocerebellar hemispheres (Middleton and Strick, 1994, 1997; Schmahmann, 1991; Schmahmann and Pandya, 1997). Corroborating this neuroanatomical evidence, physiological studies revealed a functional connection of frontal and parietal cortices with the neocerebellar hemispheres (Allen and Tsukahara, 1974). Using diffusion tensor MRI, Ramnani et al. investigated the topography of the cortico-pontine projections at the cerebral peduncle (Ramnani et al., 2005). They demonstrated the predominance of connections originating from prefrontal areas which could be further indicative of a cerebellar involvement in higher cognitive functions. In addition, efferent feedback projections from the dentate nucleus via the thalamus to prefrontal regions and from the ventrolateral and intralaminar nuclei to the posterior parietal cortex have been documented (Middleton and Strick, 1997; Schmahmann and Pandya, 1997). From this neuroanatomical basis one might posit a cerebellar involvement in central executive WM functions. In fact, a wide variety of evidence from behavioral studies in lesioned patients and normal controls as well as from neuroimaging studies corroborates this concept (Bellebaum and Daum, 2007; Ben-Yehudah et al., 2007). Moreover, given that both verbal and abstract shape WM lead to almost identical cerebellar activations, the hypothesis of an involvement within the phonological loop needs to be expanded in support of an extended role of the cerebellum in higher cognitive functions.

In Baddeley's WM model these higher cognitive functions are summarized in the central executive. Therefore, it appears conceivable that some of central executive subfunctions are candidate functions supported by the cerebellum. Several subfunctions of the central

Fig. 4. Average % signal change [2-back minus 0-back] for verbal WM and abstract WM in all functionally defined VOIs (VOIs that demonstrated suprathreshold activations in the combined verbal and abstract WM analysis). Conditions and x y z coordinates of the corresponding SPM CoMs are given underneath each particular graph.

executive have been outlined. Among others, one of the more recent and influential concepts concerning these subfunctions has been proposed by Smith and Jonides (Logan, 1985; Norman and Shallice, 1986; Smith and Jonides, 1999): directing attention to relevant information and inhibition of irrelevant information, task management (scheduling processes in complex tasks), planning a sequence of subtasks, monitoring (updating and checking contents of WM) and time coding. All these aspects of the central executive are relevant to successfully accomplishing the n-back task. Evidence of cerebellar contributions to all of these subfunctions is obtained by a variety of experimental approaches:

Attention and inhibition: studies in patients and healthy controls (Gottwald et al., 2003, 2004; Townsend et al., 1999), neuroimaging studies (Allen et al., 1997; Le et al., 1998).

Task management/multitasking: studies in patients and healthy controls (Doyon et al., 1998; Lang and Bastian, 2002; Schmahmann, 2004; Schmahmann and Sherman, 1998), neuroimaging studies (Collette et al., 2005; Hayter et al., 2007).

Planning/sequencing: animal studies (Mandolesi et al., 2001), studies in patients and healthy controls (Botez et al., 1989; Fisher et al., 2006; Grafman et al., 1992; Leggio et al., 2008; Machner et al., 2005), neuroimaging studies (Beauchamp et al., 2003; Dagher et al., 1999; Krams et al., 1998; Schall et al., 2003; Unterrainer et al., 2004). Updating: studies in patients and healthy controls (Fisher et al., 2006), neuroimaging studies (Leung et al., 2007).

Time coding: animal studies (Breukelaar and rymple-Alford, 1999), studies in patients and healthy controls (Ackermann et al., 1999; Harrington et al., 2004b), neuroimaging studies (Harrington et al., 2004a; Mathiak et al., 2002, 2004); TMS studies (Desmond et al., 2005; Koch et al., 2007; Oliveri et al., 2007).

Taken together, this produces a large body of evidence that the cerebellum contributes to the majority of the central executive subfunctions. In line with our view, Marklund et al. interpreted the cerebellum as a supportive system for the coordination of attention and anticipatory control (Marklund et al., 2007). Ferrucci et al. found that the cerebellum is involved in practice-dependent proficiency during a modified Sternberg WM task while stimulating the cerebellum by transcranial direct current prior to study (Ferrucci et al., 2008). This additionally corroborates a broader auxiliary role of the cerebellum in the executive function context. If the subsidiary functions of the phonological loop were challenged by the direct current, WM would have been impaired directly after the stimulation and the effect would have decreased slowly thereafter. Instead, the impairment was evident 35 min after stimulation. Finally, the dysmetria of thought concept associates all these higher cognitive function impairments with damage to the cerebellum and forms the neuropsychological basis of the CCAS (Schmahmann and Caplan, 2006; Schmahmann and Sherman, 1998).

Consequently, in the context of working memory, the cerebellum should not only be viewed as a neuronal system involved in the phonological loop of WM or other subordinate WM slave systems but also as a system supporting a wide variety of central executive WM subfunctions. However, its role appears to be confined to the optimization and fine-tuning of these higher cognitive functions since after prolonged damage, behavioral recovery could slowly develop (Chiricozzi et al., 2008; Justus et al., 2005). This is indicative of a functional shift to cortical structures that are also involved in the main aspects of the central executive, as demonstrated in an fMRI study (Ziemus et al., 2007).

In conclusion, the present study provides further evidence of the view that the cerebellum supports not only processes in the context of the subsidiary phonological loop system but also different higher

cognitive subfunctions in the context of the central executive. This cerebellar assistance is not only confined to verbal WM but is generalizable across WM modalities. In this way, one could perceive the cerebellum as a supportive system interacting with prefrontal and parietal brain regions in order to facilitate successful task accomplishment. Finally, when especially emphasizing the central executive aspects of WM by applying an n-back paradigm the additional slave system dependent laterality effects appear to be overridden by dominating central executive contributions of the cerebellum to the distributed cerebro-cerebellar WM network.

References

- Ackermann, H., Graber, S., Hertrich, I., Daum, I., 1999. Cerebellar contributions to the perception of temporal cues within the speech and nonspeech domain. *Brain Lang.* 67, 228–241.
- Ackermann, H., Mathiak, K., Riecker, A., 2007. The contribution of the cerebellum to speech production and speech perception: clinical and functional imaging data. *Cerebellum* 6, 202–213.
- Allen, G.L., Tsukahara, N., 1974. Cerebrocerebellar communication systems. *Physiol. Rev.* 54, 957–1006.
- Allen, G., Buxton, R.B., Wong, E.C., Courchesne, E., 1997. Attentional activation of the cerebellum independent of motor involvement. *Science* 275, 1940–1943.
- Appollonio, L.M., Grafman, J., Schwartz, V., Massaquoi, S., Hallett, M., 1993. Memory in patients with cerebellar degeneration. *Neurology* 43, 1536–1544.
- Attneave, F., Arnoult, M.D., 1956. The quantitative study of shape and pattern perception. *Psychol. Bull.* 53, 452–471.
- Awh, E., Jonides, J., Smith, E.E., Schumacher, E.H., Koeppel, R., Katz, S., 1996. Dissociation of storage and rehearsal in verbal working memory: Evidence from PET. *Psychol. Sci.* 7, 25–31.
- Baddeley, A.D., 1986. *Working Memory*. Oxford University Press.
- Baddeley, A., 2000. The episodic buffer: a new component of working memory? *Trends. Cogn. Sci.* 4, 417–423.
- Baddeley, A.D., Hitch, G., 1974. Working memory. In: Bower, G.A. (Ed.), *The Psychology of Learning and Motivation*, 1st ed. Academic Press, New York, pp. 47–89.
- Beauchamp, M.H., Dagher, A., Aston, J.A., Doyon, J., 2003. Dynamic functional changes associated with cognitive skill learning of an adapted version of the Tower of London task. *NeuroImage* 20, 1649–1660.
- Bellebaum, C., Daum, I., 2007. Cerebellar involvement in executive control. *Cerebellum* 6, 184–192.
- Ben-Yehudah, G., Guediche, S., Fiez, J.A., 2007. Cerebellar contributions to verbal working memory: beyond cognitive theory. *Cerebellum* 6, 193–201.
- Botez, M.I., Botez, T., Elie, R., Attig, E., 1989. Role of the cerebellum in complex human behavior. *Ital. J. Neurol. Sci.* 10, 291–300.
- Botez-Marquard, T., Leveille, J., Botez, M.I., 1994. Neuropsychological functioning in unilateral cerebellar damage. *Can. J. Neurol. Sci.* 21, 353–357.
- Breukelaar, J.W., rymple-Alford, J.C., 1999. Effects of lesions to the cerebellar vermis and hemispheres on timing and counting in rats. *Behav. Neurosci.* 113, 78–90.
- Broich, K., Hartmann, A., Biersack, H.J., Horn, R., 1987. Crossed cerebello-cerebral diaschisis in a patient with cerebellar infarction. *Neurosci. Lett.* 83, 7–12.
- Cabeza, R., Nyberg, L., 2000. Imaging cognition II: an empirical review of 275 PET and fMRI studies. *J. Cogn. Neurosci.* 12, 1–47.
- Chen, S.H., Desmond, J.E., 2005a. Cerebrocerebellar networks during articulatory rehearsal and verbal working memory tasks. *NeuroImage* 24, 332–338.
- Chen, S.H., Desmond, J.E., 2005b. Temporal dynamics of cerebro-cerebellar network recruitment during a cognitive task. *Neuropsychologia* 43, 1227–1237.
- Chiricozzi, F.R., Clausi, S., Molinari, M., Leggio, M.G., 2008. Phonological short-term store impairment after cerebellar lesion: a single case study. *Neuropsychologia* 46, 1940–1953.
- Collette, F., Olivier, L., Van der, L.M., Laureys, S., Delfiore, G., Luxen, A., Salmon, E., 2005. Involvement of both prefrontal and inferior parietal cortex in dual-task performance. *Brain Res. Cogn. Brain Res.* 24, 237–251.
- Courtney, S.M., Ungerleider, L.G., Keil, K., Haxby, J.V., 1996. Object and spatial visual working memory activate separate neural systems in human cortex. *Cereb. Cortex* 6, 39–49.
- D'Esposito, M., Postle, B.R., Rypma, B., 2000. Prefrontal cortical contributions to working memory: evidence from event-related fMRI studies. *Exp. Brain Res.* 133, 3–11.
- Dagher, A., Owen, A.M., Boecker, H., Brooks, D.J., 1999. Mapping the network for planning: a correlational PET activation study with the Tower of London task. *Brain* 122 (Pt. 10), 1973–1987.
- Desmond, J.E., Fiez, J.A., 1998. Neuroimaging studies of the cerebellum: language, learning and memory. *Trends Cogn. Sci.* 2, 355–362.
- Desmond, J.E., Gabrieli, J.D., Wagner, A.D., Ginier, B.L., Glover, G.H., 1997. Lobular patterns of cerebellar activation in verbal working-memory and finger-tapping tasks as revealed by functional MRI. *J. Neurosci.* 17, 9675–9685.
- Desmond, J.E., Chen, S.H., DeRosa, E., Pryor, M.R., Pfefferbaum, A., Sullivan, E.V., 2003. Increased frontocerebellar activation in alcoholics during verbal working memory: an fMRI study. *NeuroImage* 19, 1510–1520.
- Desmond, J.E., Chen, S.H., Shieh, P.B., 2005. Cerebellar transcranial magnetic stimulation impairs verbal working memory. *Ann. Neurol.* 58, 553–560.
- Dimitrova, A., Zeljko, D., Schwarze, F., Maschke, M., Gerwig, M., Frings, M., Beck, A., Aurich, V., Forsting, M., Timmann, D., 2006. Probabilistic 3D MRI atlas of the human cerebellar dentate/interposed nuclei. *NeuroImage* 30, 12–25.

- Doyon, J., Laforce Jr., R., Bouchard, G., Gaudreau, D., Roy, J., Poirier, M., Bedard, P.J., Bedard, F., Bouchard, J.P., 1998. Role of the striatum, cerebellum and frontal lobes in the automatization of a repeated visuomotor sequence of movements. *Neuropsychologia* 36, 625–641.
- Ferrucci, R., Marceglia, S., Vergari, M., Cogiamanian, F., Mrakic-Sposta, S., Mameli, F., Zago, S., Barbieri, S., Priori, A., 2008. Cerebellar transcranial direct current stimulation impairs the practice-dependent proficiency increase in working memory. *J. Cogn. Neurosci.* 20, 1687–1697.
- Fiez, J.A., 2001a. Bridging the gap between neuroimaging and neuropsychology: using working memory as a case-study. *J. Clin. Exp. Neuropsychol.* 23, 19–31.
- Fiez, J.A., 2001b. Neuroimaging studies of speech an overview of techniques and methodological approaches. *J. Commun. Disord.* 34, 445–454.
- Fisher, B.E., Boyd, L., Winstein, C.J., 2006. Contralateral cerebellar damage impairs imperative planning but not updating of aimed arm movements in humans. *Exp. Brain Res.* 174, 453–466.
- Gottwald, B., Mihajlovic, Z., Wilde, B., Mehdorn, H.M., 2003. Does the cerebellum contribute to specific aspects of attention? *Neuropsychologia* 41, 1452–1460.
- Gottwald, B., Wilde, B., Mihajlovic, Z., Mehdorn, H.M., 2004. Evidence for distinct cognitive deficits after focal cerebellar lesions. *J. Neurol. Neurosurg. Psychiatry* 75, 1524–1531.
- Grafman, J., Litvan, I., Massaquoi, S., Stewart, M., Sirigu, A., Hallett, M., 1992. Cognitive planning deficit in patients with cerebellar atrophy. *Neurology* 42, 1493–1496.
- Gruber, O., 2001. Effects of domain-specific interference on brain activation associated with verbal working memory task performance. *Cereb. Cortex* 11, 1047–1055.
- Gruber, O., von Cramon, D.Y., 2003. The functional neuroanatomy of human working memory revisited. Evidence from 3-T fMRI studies using classical domain-specific interference tasks. *Neuroimage* 19, 797–809.
- Haarmeier, T., Thier, P., 2007. The attentive cerebellum — myth or reality? *Cerebellum* 6, 177–183.
- Harrington, D.L., Boyd, L.A., Mayer, A.R., Sheltraw, D.M., Lee, R.R., Huang, M., Rao, S.M., 2004a. Neural representation of interval encoding and decision making. *Brain Res. Cogn. Brain Res.* 21, 193–205.
- Harrington, D.L., Lee, R.R., Boyd, L.A., Rapsak, S.Z., Knight, R.T., 2004b. Does the representation of time depend on the cerebellum? Effect of cerebellar stroke. *Brain* 127, 561–574.
- Hautzel, H., Mottaghy, F.M., Schmidt, D., Zemb, M., Shah, N.J., Muller-Gartner, H.W., Krause, B.J., 2002. Topographic segregation and convergence of verbal, object, shape and spatial working memory in humans. *Neurosci. Lett.* 323, 156–160.
- Hautzel, H., Mottaghy, F.M., Schmidt, D., Müller, H.W., Krause, B.J., 2003. Neurocognition and PET: strategies for data analysis in activation studies on working memory. *Nuklearmedizin* 42, 197–209.
- Hayter, A.L., Langdon, D.W., Ramnani, N., 2007. Cerebellar contributions to working memory. *Neuroimage* 36, 943–954.
- Hokkanen, L.S., Kauranen, V., Roine, R.O., Salonen, O., Kotila, M., 2006. Subtle cognitive deficits after cerebellar infarcts. *Eur. J. Neurol.* 13, 161–170.
- Justus, T., Ravizza, S.M., Fiez, J.A., Ivry, R.B., 2005. Reduced phonological similarity effects in patients with damage to the cerebellum. *Brain Lang.* 95, 304–318.
- Kirschen, M.P., Chen, S.H., Schraedley-Desmond, P., Desmond, J.E., 2005. Load- and practice-dependent increases in cerebro-cerebellar activation in verbal working memory: an fMRI study. *Neuroimage* 24, 462–472.
- Koch, G., Oliveri, M., Torriero, S., Salerno, S., Lo, G.E., Caltagirone, C., 2007. Repetitive TMS of cerebellum interferes with millisecond time processing. *Exp. Brain Res.* 179, 291–299.
- Krams, M., Rushworth, M.F., Deiber, M.P., Frackowiak, R.S., Passingham, R.E., 1998. The preparation, execution and suppression of copied movements in the human brain. *Exp. Brain Res.* 120, 386–398.
- Krause, B.J., Hautzel, H., Schmidt, D., Fluss, M.O., Poeppel, T.D., Muller, H.W., Halsband, U., Mottaghy, F.M., 2006. Learning related interactions among neuronal systems involved in memory processes. *J. Physiol. Paris* 99, 318–332.
- Lang, C.E., Bastian, A.J., 2002. Cerebellar damage impairs automaticity of a recently practiced movement. *J. Neurophysiol.* 87, 1336–1347.
- Le, T.H., Pardo, J.V., Hu, X., 1998. A 4-T fMRI study of nonspatial shifting of selective attention: cerebellar and parietal contributions. *J. Neurophysiol.* 79, 1535–1548.
- Leggio, M.G., Tedesco, A.M., Chiricozzi, F.R., Clausi, S., Orsini, A., Molinari, M., 2008. Cognitive sequencing impairment in patients with focal or atrophic cerebellar damage. *Brain* 131, 1332–1343.
- Leung, H.C., Oh, H., Ferri, J., Yi, Y., 2007. Load response functions in the human spatial working memory circuit during location memory updating. *Neuroimage* 35, 368–377.
- Logan, G., 1985. Executive control of thought. *Acta Psychologica* 60, 193–210.
- Machner, B., Sprenger, A., Kompf, D., Heide, W., 2005. Cerebellar infarction affects visual search. *Neuroreport* 16, 1507–1511.
- Maldjian, J.A., Laurienti, P.J., Kraft, R.A., Burdette, J.H., 2003. An automated method for neuroanatomic and cytoarchitectonic atlas-based interrogation of fMRI data sets. *Neuroimage* 19, 1233–1239.
- Maldjian, J.A., Laurienti, P.J., Burdette, J.H., 2004. Precentral gyrus discrepancy in electronic versions of the Talairach atlas. *Neuroimage* 21, 450–455.
- Mandolesi, L., Leggio, M.G., Graziano, A., Neri, P., Petrosini, L., 2001. Cerebellar contribution to spatial event processing: involvement in procedural and working memory components. *Eur. J. Neurosci.* 14, 2011–2022.
- Marien, P., Engelborghs, S., De Deyn, P.P., 2001. Cerebellar neurocognition: a new avenue. *Acta Neurol. Belg.* 101, 96–109.
- Marklund, P., Fransson, P., Cabeza, R., Larsson, A., Ingvar, M., Nyberg, L., 2007. Unity and diversity of tonic and phasic executive control components in episodic and working memory. *Neuroimage* 36, 1361–1373.
- Mathiak, K., Hertrich, I., Grodd, W., Ackermann, H., 2002. Cerebellum and speech perception: a functional magnetic resonance imaging study. *J. Cogn. Neurosci.* 14, 902–912.
- Mathiak, K., Hertrich, I., Grodd, W., Ackermann, H., 2004. Discrimination of temporal information at the cerebellum: functional magnetic resonance imaging of nonverbal auditory memory. *Neuroimage* 21, 154–162.
- Middleton, F.A., Strick, P.L., 1994. Anatomical evidence for cerebellar and basal ganglia involvement in higher cognitive function. *Science* 266, 458–461.
- Middleton, F.A., Strick, P.L., 1997. Cerebellar output channels. In: Schmähmann, J.D. (Ed.), *International Review of Neurobiology on the Cerebellum and Cognition*, Vol. 41. Academic Press, San Diego, pp. 61–83.
- Mottaghy, F.M., 2006. Interfering with working memory in humans. *Neuroscience* 139, 85–90.
- Norman, D.A., Shallice, T., 1986. Attention to action: willed and automatic control of behavior. In: Davidson, R.J., Schwartz, G.E., Shapiro, D. (Eds.), *Consciousness and Self Regulation*, Vol. 4. Plenum, New York, pp. 1–18.
- Nystrom, L.E., Braver, T.S., Sabb, F.W., Delgado, M.R., Noll, D.C., Cohen, J.D., 2000. Working memory for letters, shapes, and locations: fMRI evidence against stimulus-based regional organization in human prefrontal cortex. *Neuroimage* 11, 424–446.
- Oliveri, M., Torriero, S., Koch, G., Salerno, S., Petrosini, L., Caltagirone, C., 2007. The role of transcranial magnetic stimulation in the study of cerebellar cognitive function. *Cerebellum* 6, 95–101.
- Owen, A.M., McMillan, K.M., Laird, A.R., Bullmore, E., 2005. N-back working memory paradigm: a meta-analysis of normative functional neuroimaging studies. *Hum. Brain Mapp.* 25, 46–59.
- Pantano, P., Baron, J.C., Samson, Y., Bousser, M.G., Derouesne, C., Comar, D., 1986. Crossed cerebellar diaschisis. *Further Stud. Brain* 109 (Pt 4), 677–694.
- Paulesu, E., Frith, C.D., Frackowiak, R.S., 1993. The neural correlates of the verbal component of working memory. *Nature* 362, 342–345.
- Pessoa, L., Ungerleider, L.G., 2004. Neural correlates of change detection and change blindness in a working memory task. *Cereb. Cortex* 14, 511–520.
- Peters, J., Suchan, B., Zhang, Y., Daum, I., 2005. Visuo-verbal interactions in working memory: evidence from event-related potentials. *Brain Res. Cogn. Brain Res.* 25, 406–415.
- Petersen, S.E., Fox, P.T., Posner, M.I., Mintun, M., Raichle, M.E., 1988. Positron emission tomographic studies of the cortical anatomy of single-word processing. *Nature* 331, 585–589.
- Petrides, M., Alivisatos, B., Evans, A.C., Meyer, E., 1993a. Dissociation of human mid-dorsolateral from posterior dorsolateral frontal cortex in memory processing. *Proc. Natl. Acad. Sci. U.S.A.* 90, 873–877.
- Petrides, M., Alivisatos, B., Meyer, E., Evans, A.C., 1993b. Functional activation of the human frontal cortex during the performance of verbal working memory tasks. *Proc. Natl. Acad. Sci. U.S.A.* 90, 878–882.
- Ramnani, N., Behrens, T.E., Johansen-Berg, H., Richter, M.C., Pinski, M.A., Andersson, J.L., Rudebeck, P., Ciccirelli, O., Richter, W., Thompson, A.J., Gross, C.G., Robson, M.D., Kastner, S., Matthews, P.M., 2005. The evolution of prefrontal inputs to the cortico-pontine system: diffusion imaging evidence from macaque monkeys and humans. *Cereb. Cortex* 16, 811–818.
- Ravizza, S.M., McCormick, C.A., Schlerf, J.E., Justus, T., Ivry, R.B., Fiez, J.A., 2006. Cerebellar damage produces selective deficits in verbal working memory. *Brain* 129, 306–320.
- Repovs, G., Baddeley, A., 2006. The multi-component model of working memory: explorations in experimental cognitive psychology. *Neuroscience* 139, 5–21.
- Rypma, B., Prabhakaran, V., Desmond, J.E., Glover, G.H., Gabrieli, J.D., 1999. Load-dependent roles of frontal brain regions in the maintenance of working memory. *Neuroimage* 9, 216–226.
- Salmon, E., Van der, L.M., Collette, F., Delfiore, G., Maquet, P., Degueldre, C., Luxen, A., Franck, G., 1996. Regional brain activity during working memory tasks. *Brain* 119 (Pt. 5), 1617–1625.
- Schall, U., Johnston, P., Lagopoulos, J., Juptner, M., Jentzen, W., Thienel, R., ttman-Balcar, A., Bender, S., Ward, P.B., 2003. Functional brain maps of Tower of London performance: a positron emission tomography and functional magnetic resonance imaging study. *Neuroimage* 20, 1154–1161.
- Schirmer, A., 2004. Timing speech: a review of lesion and neuroimaging findings. *Brain Res. Cogn. Brain Res.* 21, 269–287.
- Schmahmann, J.D., 1991. An emerging concept. The cerebellar contribution to higher function. *Arch. Neurol.* 48, 1178–1187.
- Schmahmann, J.D., 2004. Disorders of the cerebellum: ataxia, dysmetria of thought, and the cerebellar cognitive affective syndrome. *J. Neuropsychiatry Clin. Neurosci.* 16, 367–378.
- Schmahmann, J.D., Caplan, D., 2006. Cognition, emotion and the cerebellum. *Brain* 129, 290–292.
- Schmahmann, J.D., Pandya, D.N., 1997. The cerebrocerebellar system. *Int. Rev. Neurobiol.* 41, 51–60.
- Schmahmann, J.D., Doyon, J., McDonald, D., Holmes, C., Lavoie, K., Hurwitz, A.S., Kabani, N., Toga, A., Evans, A., Petrides, M., 1999. Three-dimensional MRI atlas of the human cerebellum in proportional stereotaxic space. *Neuroimage* 10, 233–260.
- Schmahmann, J.D., Doyon, J., Toga, A.W., Petrides, M., Evans, A.C., 2000. *MRI Atlas of the Cerebellum*. Academic Press, San Diego.
- Schmahmann, J.D., Sherman, J.C., 1998. The cerebellar cognitive affective syndrome. *Brain* 121 (Pt. 4), 561–579.
- Smith, E.E., Jonides, J., 1997. Working memory: a view from neuroimaging. *Cognit. Psychol.* 33, 5–42.
- Smith, E.E., Jonides, J., 1999. Storage and executive processes in the frontal lobes. *Science* 283, 1657–1661.
- Smith, E.E., Jonides, J., Marshuetz, C., Koeppel, R.A., 1998. Components of verbal working memory: evidence from neuroimaging. *Proc. Natl. Acad. Sci. U. S. A.* 95, 876–882.

- Suchan, B., 2008. Neuroanatomical correlates of processing in visual and visuospatial working memory. *Cogn. Process.* 9, 45–51.
- Timmann, D., Daum, I., 2007. Cerebellar contributions to cognitive functions: a progress report after two decades of research. *Cerebellum* 6, 159–162.
- Townsend, J., Courchesne, E., Covington, J., Westerfield, M., Harris, N.S., Lyden, P., Lowry, T.P., Press, G.A., 1999. Spatial attention deficits in patients with acquired or developmental cerebellar abnormality. *J. Neurosci.* 19, 5632–5643.
- Unterrainer, J.M., Rahm, B., Kaller, C.P., Ruff, C.C., Spreer, J., Krause, B.J., Schwarzwald, R., Hautzel, H., Halsband, U., 2004. When planning fails: individual differences and error-related brain activity in problem solving. *Cereb. Cortex* 14, 1390–1397.
- Wager, T.D., Smith, E.E., 2003. Neuroimaging studies of working memory: a meta-analysis. *Cogn. Affect. Behav. Neurosci.* 3, 255–274.
- Ziemus, B., Baumann, O., Luerding, R., Schlosser, R., Schuierer, G., Bogdahn, U., Greenlee, M.W., 2007. Impaired working-memory after cerebellar infarcts paralleled by changes in BOLD signal of a cortico-cerebellar circuit. *Neuropsychologia* 45, 2016–2024.